

# The effect of diazinon exposure on hepatic tissue and enzymes in male frog *Rana ridibunda*

Received: 6 February, 2014; Accepted: 23 September, 2015

Leila Ghasemzadeh<sup>1</sup>, Hamidreza Mohajereani<sup>2\*</sup>, Sima Nasri<sup>3</sup> and Alireza Rostami<sup>4</sup>

1. M.S. Payamenoor University, Iran

2. Assistant professor, Department of Biology, Faculty of Science, Islamic Azad University, Arak Branch, Arak, Iran

3. Associate Professor, Biology Department, PayamNoor University, 19395-4697 Tehran, Iran

4. Assistant Professor, Cardiac Surgery Department, Arak University of Medical Science, Iran

## ABSTRACT

The purpose of this study was to examine the acute and sub-acute effects of diazinon on histopathological parameters of liver tissue and blood level of hepatic enzymes of male common frog (*Rana ridibunda*). Frogs were assigned to 9 groups (n=8, meaning 8 frogs in each group): control and treatment groups with 30, 60, 90 and 120 µg/L diazinon in water for one day or one week. Hepatic enzymes containing alanine transaminase (ALT), aspartate aminotransferase (AST), and alkaline phosphatase (ALP) were measured using biochemical kit. All ALP values were significantly different between the control group and one-day and one-week diazinon exposed groups. Hepatocyte changes were observed only for diazinon concentrations greater than 60 µl after one week. The most important characteristics of the affected cells were hyperplasia and chromatin formation. Results show that sub-lethal concentrations of diazinon have an increasing effect on the blood level of hepatic enzymes, which probably indicated the detoxification response of liver on the basis of diazinon sub-lethal effect model.

**Keywords:** diazinon, hepatic enzymes, liver tissue.

\* Corresponding author: mohajerani@gmail.com

## Introduction

Diazinon is an organophosphorus pesticide, which is extensively used in agricultural activities (1). It was known as a harmful environmental pollutant (2). It is easily washed and distributed in rivers and wetlands near the farms and affects the animals' life (3). Percutaneous absorption of diazinon resulted in hepatotoxicity in human (4), rabbit and rat (5, 6, 7, 8). It is water insoluble and degrades rapidly, but it may be sustainable under special circumstances as low temperature, high alkalinity, dryness, and lack of microbiological degraders (3). In aquatic ecosystems, fishes and amphibians are orally and cutaneously exposed to this toxin (9).

*Rana ridibunda* has an important location in food chains of freshwater ecosystems. This species distributes extensively in Europe and Asia from Asian Russia to Afghanistan, Pakistan and China. Elevated liver enzymes are the sign of inflammation in the liver. Alanine transaminase (ALT), also called serum glutamic pyruvate transaminase (SGPT), is an enzyme present in hepatocytes (liver cells). Aspartate transaminase, also called serum glutamic oxaloacetic transaminase (SGOT) or aspartate aminotransferase (AST), is similar to ALT in that it is another enzyme associated with liver parenchymal cells. Alkaline phosphatase (ALP) is an enzyme in cells lining the biliary ducts of the liver. ALP levels in plasma will increase with infiltrative diseases of the liver (10).

After 24h, different doses of diazinon between 25 and 250 mg/kg resulted in the increase of AST, ALT, amylase, lipase, and cholinesterase, but lactate dehydrogenase (LDH) was higher in 100 and 200 mg/kg group when compared with the control group. Diazinon 300 mg/kg concentration had a complete fatal effect on rats.

Histopathological changes were only observed for 200 mg/kg diazinon. These evidences show dose dependent effect of about 10 to 15% of LD50 (200 mg/kg), which resulted in pancreatitis and histopathological changes in rat liver (11). Liver intoxication of diazinon increased AST, ALT and ALP in rat blood serum. Sub-lethal concentration of diazinon significantly decreased gill, muscle, kidney and liver of ALT and AST in *Clarias gariepinus* (12).

The aim of this study was to examine the acute and sub-acute effects of diazinon on histopathological parameters of liver tissue and blood level of hepatic enzymes of male common frog (*R. ridibunda*). This is the first study that reports the histological and hepatic enzymes effect of diazinon on this species.

## Materials and Methods

Diazinon with IUPAC name of O,O-Diethyl O-[4-methyl-6-(propan-2-yl)pyrimidin-2-yl] phosphorothioate with 60% purity (dissolved in acetone) was purchased from Chemical Services (Sadat Mahan company, Iran).

Adult male *R. ridibunda* frogs weighting 100 to 150g were collected from Anzali wetland (37° 28' 16" N, 49° 27' 44" E). Fiberglass tanks with 20 L capacity were used to keep these frogs under laboratory conditions (25°C, 12 h light and 12 h dark). Male frogs were selected and kept in tanks filled with diazinon free water (Table 1) for 168 h (one week), because of simple handling and hormonal stability. After this period, none of the frogs died and they were respected as experimental group.

Water quality characteristics of the reservoir in the experimental media were determined according to American Public Health Association (APHA, 1992).

**Table 1. Diazinon free water characteristics**

Factors	Values
pH	7.9
Electrical conductivity	2.11
Nitrite	0.062 PPM
Nitrate	0.14 PPM
Hardness	85
Temperature	25

**Table 2. Lethality percent after 96 h in different doses of diazinon.**

Lethality percent after 96 h	Diazinon concentration ( $\mu\text{g/L}$ )
100%	210
80%	180
20%	150
0%	120

Diazinon concentrations of 30, 60, 90 and 120  $\mu\text{g/L}$  were prepared from the stock solution. To determine the lethal limit, frogs were incubated for 96 h in different doses of diazinon as indicated below in basis of Organisation for Economic Co-operation and Development (OECD, 1992) (Table 2).

Frogs were assigned to 9 groups ( $n=8$ , meaning 8 frogs in each group): control group (frogs kept in free diazinon water) and treatment groups (frogs kept with 30, 60, 90 and 120  $\mu\text{g/L}$  diazinon in water for one day or one week). After the exposure time, frogs were pitted and blood samples were gotten from their heart. Blood samples were collected in microtubes and were centrifuged (2500 rpm for 10 min). Hepatic enzymes containing ALT, AST, and ALP were measured by biochemical kit and Deutsche Gesellschaft für Klinische Chemie protocol (Pars Azmoon Company, Iran) using photometric method. Photometer was calibrated for wavelength of 405 nm (for ALP), and 340 nm (for AST and ALT) at 37°C temperature and cuvette diameter of 1 cm.

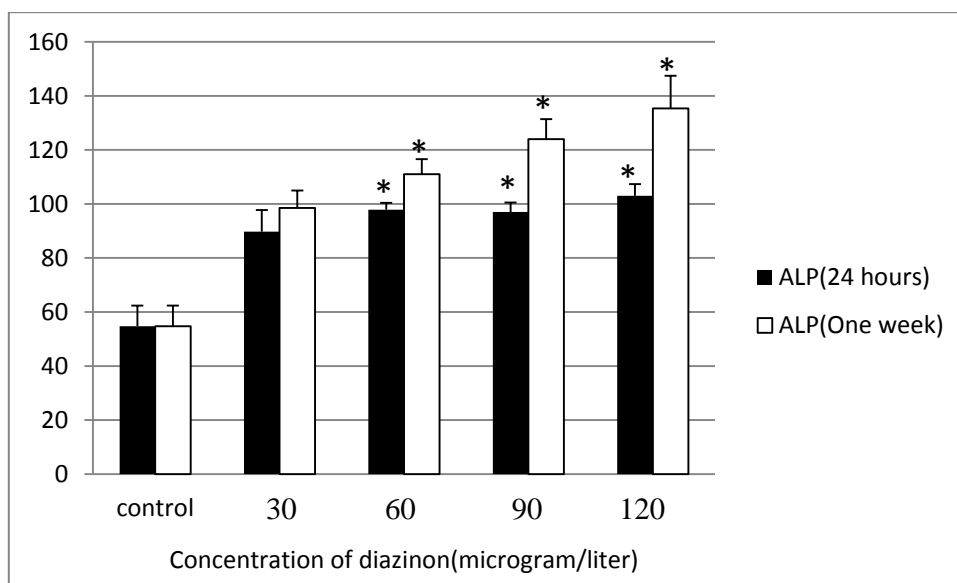
Liver tissues were removed and washed

out using frog ringer and were fixed by 12% formalin and thereafter were colored using Hematoxylin and Eosin (H&E) and reticulum staining methods. Statistical software package SPSS (Version 14.0, SPSS Chicago, Illinois, USA) was used to compare the control and exposure groups. One-way analysis of variance (ANOVA) and Tukey test post hoc were used for the analysis.

## Results

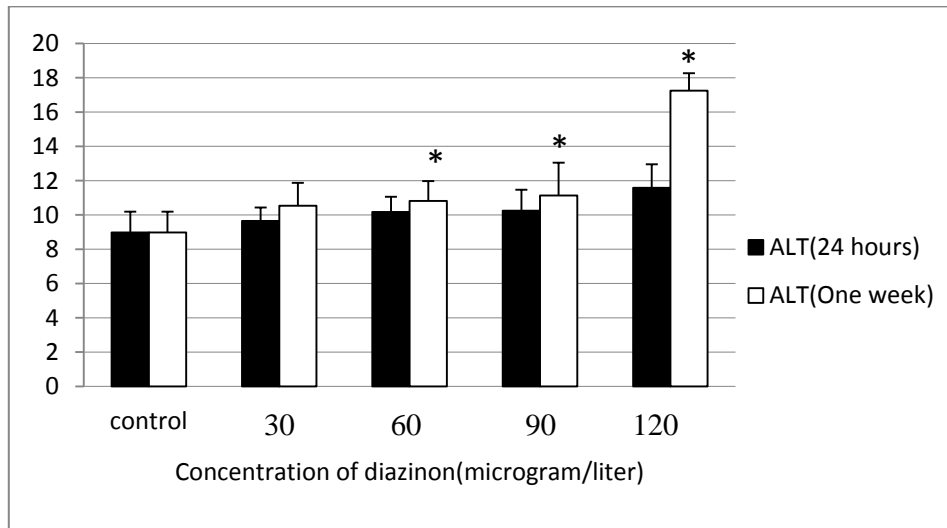
When checking for the effect of diazinon on the liver enzymes blood level for ALP, significant differences were observed for the control and diazinon exposed groups ( $P<0.05$ ) at one day and one week (Fig. 1). Significant differences were observed for ALT values between the control and diazinon exposed groups ( $P<0.05$ ) for one week after 60, 90 and 120  $\mu\text{g/L}$  diazinon exposure (Fig. 2).

Significant differences were observed for AST values between the control and diazinon exposed groups ( $P<0.05$ ) for one week of 60, 90 and 120  $\mu\text{g/L}$  diazinon (Fig. 3).



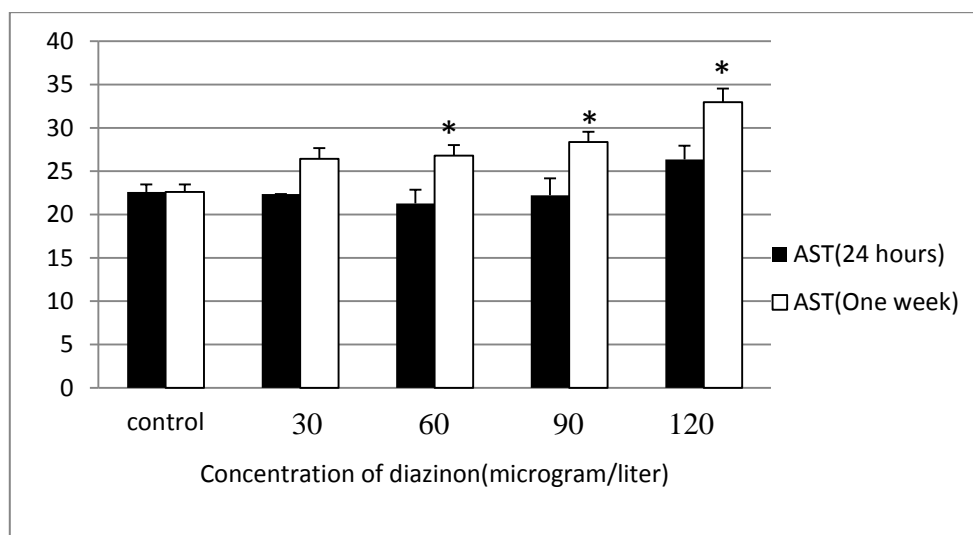
**Figure 1.** The mean of ALP enzyme level per 30, 60, 90 and 120 µg/L diazinon after 24 h and one week ( $P<0.05$ ). The values are expressed as mean±standard error (SE)

\* $P<0.05$  (The difference of ALP enzyme with control group)



**Figure 2.** The mean of ALT enzyme level per 30, 60, 90 and 120 µg/L diazinon after 24 h and one week ( $P<0.05$ ). The values are expressed as mean±standard error (SE)

\* $P<0.05$  (The difference of ALT enzyme level with control group)

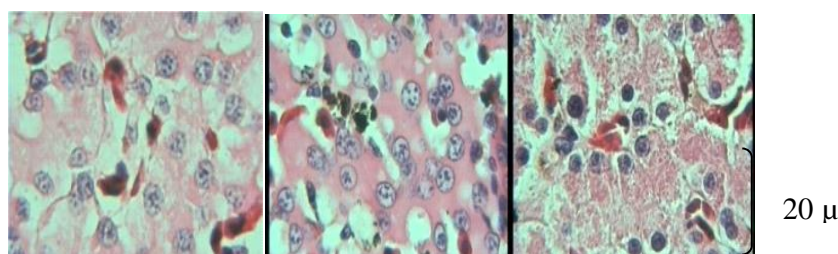


**Figure 3.** The mean of AST enzyme level per 30, 60, 90 and 120 µg/L diazinon after 24 h and one week ( $P<0.05$ ). The values are expressed as mean±standard error (SE)

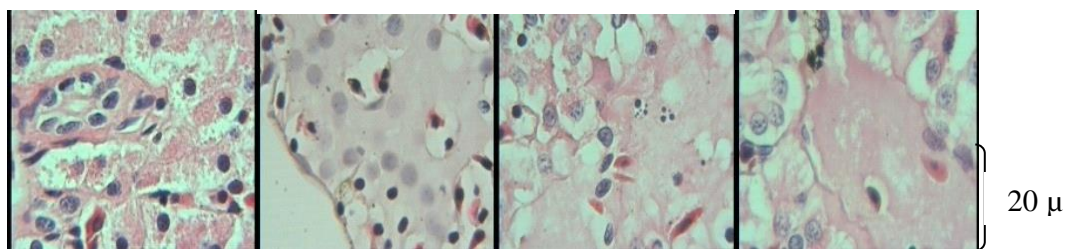
\* $P<0.05$  (The difference of AST enzyme level with control group)

In the control group, the hepatocytes had distinct cell walls. Changes in hepatocyte were observed for only diazinon concentrations greater than 60 µl after one week. The most important characteristics of affected cells were hyperplasia and chromatin formation (Fig. 4). These changes were dose dependent for 60, 90 and 120 µg/L diazinon. Diazinon (120 µg/L) for one week resulted in deformation of geometric shape of hepatocytes (Fig. 5) and the hepatic tissue was fragile, therefore sections were prepared with difficulty.

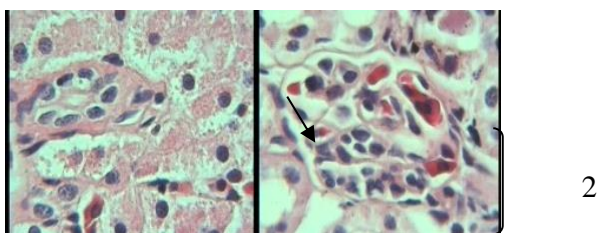
Hyperplasia was also observed in Kupffer cells and they entered mitotic stage (Fig. 6). In the affected tissue, both direct necrosis and regeneration of hepatocytes were observable simultaneously, but no cell group necrosis. Regenerative indices were sinusoid hyperplasia and mitosis (Fig. 7). Reticulum staining indicated obvious degeneration and gradual necrosis of hepatocytes (Fig. 8). Cytoplasm degradation of hepatocytes and formation of vesicular vacuoles were observed in concentrations greater than 60 µg/L of diazinon for one week (Fig. 9).



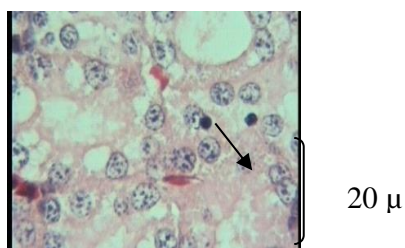
**Figure 4.** From left to right: 0 (control), 90 and 120 µg/L diazinon for one week. In comparison with the control group, chromatin were condensed and their diameters were increased; H&E staining,  $\times 40$ .



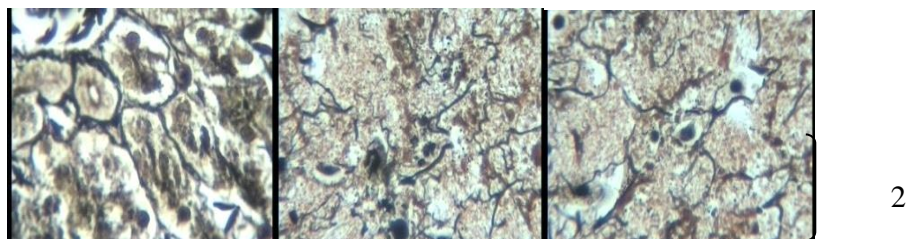
**Figure 5.** Gradual changes and necrosis of hepatic tissues that were exposed to 0, 60, 90, and 120 µg/L diazinon (left to right respectively) for one week; H&E staining, × 40.



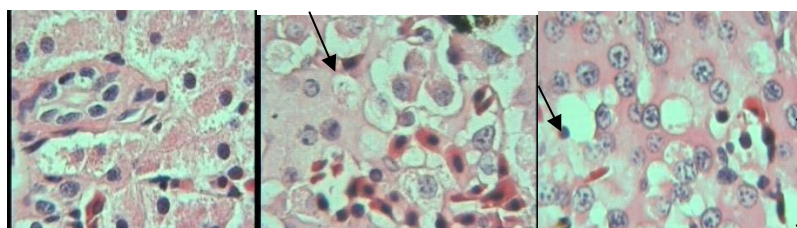
**Figure 6.** Normal Kupffer cells of the control group hepatic tissue (Left): Hyperplastic Kupffer cells of 120 µg/L diazinon exposed for one week (Right); H&E staining, × 40.



**Figure 7.** Necrosis and increase of the mitosis in hepatic tissue of 120 µg/L diazinon for one week; H&E staining, × 40



**Figure 8.** Reticulum stained hepatocytes, from left to right, 0 (control), 90 and 120 µg/L diazinon for one week, gradual necrosis of hepatocytes are visible; Reticulum staining, × 40



2

**Figure 9.** Cytoplasm degradation and formation of fat containing vesicular vacuoles in tissues that were exposed to 0, 90 (left) and 120 (right) µg/L of diazinon for one week; H&E staining, × 40

## Discussion

Though, major part of diazinon can be absorbed by kidneys, but it is oxidized more by hepatic microsomal enzymes and produces strong acetylcholine esterase inhibitors e.g. diazoxone, hydroxy diazoxone and hydroxy diazinon (13).

Detoxification of toxins is done with oxon hydrolysis using calcium dependent esterase and/or hydrolysis using carboxyl esterases (14).

Diazinon influences the transportation of materials across mitochondrial membrane and disturbs the activity of p450 cytochrome system in hepatocytes, and releases free radicals by electronic attack to intracellular elements (15, 16, 17). Diazinon has a negative effect on protein and nucleic acid metabolism in liver, dose and time dependently (18).

In the present study, serum enzymes containing ALP, ALT, and AST were considered as liver injury indices. Although, these enzymes are not necessarily specific, but the increase of their enzymes activity results in liver injury (10). Organophosphorous insecticides e.g. diazinon, can increase ALP, ALT and AST activity and this effect is time and dose dependent (14).

Possibly, the high serum level of ALP of some diazinon treated groups was due to cessation of bile acids secretion and for ALT

and AST, it was due to necrosis of hepatocytes. Morowati (1997) studied the toxicity of thimet (phorate) in male Swiss albino mice and Gomes (1999) reported that organophosphorus pesticide induced hepatic injury that could increase these hepatic enzymes (5, 6).

ALP activity is related to hepatic isoenzymes and the increase of this enzyme is due to cholestase activity and the stopping of bile acids secretion. AST activity was observed in the mitochondria of all the cells and the increase of this activity could be related to hepatic or cardiac muscle lesions. Blood ALT activity would increase when hepatic cells are necrotic and cell membrane is destructed (19). Similar results indicated that the blood activity of ALT, AST and ALP were observed to increase in rats intoxicated with diazinon (12). In addition to these results, fat change of hepatocytes and hyperemia of triad vasculature and central vein were observed in coetaneous diazinon toxicities rabbits (8). To support these results, blood activity of ALT, AST and ALP were increased following the application of 25, 50 and 250 mg/kg diazinon in rat (11). In contrast to this study, 32.5 mg/kg diazinon resulted in reduction of ALP and AST and choline esterase, malate and lactate dehydrogenase and keratin kinase (20).

Pathological results were hepatocytes necrosis, fat changes, etc., observed in some

sections, but regeneration activity, that is, nuclear change, polynuclei in area unit and great nuclei with low cytosolic material, were observed. These changes with simultaneous increase of some hepatic enzymes indicated that hepatocytes have been injured and they began the regeneration phase in response to diazinon exposure (11).

Formation of vesicular vacuoles in tissues that were exposed to 90 and 120 µg/L diazinon for one week may be due to increase of fat in hepatocytes (21). In different stages of staining, these fats have been depleted from fat deposited vacuoles and were observable as a form of vesicular vacuoles.

Hyperplasia of Kupffer cells in 120 µg/L diazinon for the one week group shows that they entered the mitotic stage as an activation of the immune response to diazinon toxicity. Organophosphorous toxins e.g diazinon can decrease protein synthesis and fat hydrolysis. These can lead to fat change and necrosis of hepatocyte (5, 22, 23).

After 24h of exposure to 200 mg/kg diazinon, the rats showed necrosis in hepatic and pancreatic tissues. A similar reported study of diazinon intoxicated rats described these changes in hepatic tissue as well as cellular infiltration, mostly mononucleolar cells, and early formation of new bile ducts

(11). It is interesting to note that similar changes were observed in the liver of *R. ridibunda* after exposure to cadmium in an experimental model which established a direct connection between cadmium toxicity and mitochondrial membrane potential increase (24).

In conclusion, as a sub-acute model of sub-lethal concentrations of diazinon exposure, it shows its increasing effect on the blood level of hepatic enzymes. Activity of AST, ALT and ALP enzymes were in agreement with the degeneration and repair of hepatocytes. The morphological and intracellular changes of hepatocytes were observed dose dependently, which possibly show the detoxification response of hepatic tissue.

## Acknowledgements

The authors greatly appreciate the laboratory assistance of Mr. Mehdi Mohajerani and Mr. Mohammad Alimohammadi.

# REFERENCES

1. Dutta, H.M., Meijer, H.J. (2003). Sublethal effects of diazinon on the structure of the testis of bluegill, *Lepomis microchirus*: a microscopic analysis. *Environ. Pollut.*, 125, 355-360.
2. Hill, E.F., D.J., Rattner, B.A., Burton Jr. G. A., Cairns Jr. J. (2003). Wildlife toxicology of organ phosphorus and carbamate pesticides. In: Hoffman, (Eds), *Handbook of Ecotoxicology*. Lewis Publishers., Boca Raton. USA.
3. Eisler, R. (1986). The effect of diazinon on hematological indices of common carp (*Cyprinus carpio* L.), *Bull. Environ. Contam. Toxicol.*, 58, 135-141.
4. Garfitt, S. J., Jones, K., Mason, H. J., Cocker, J. (2002). Exposure to the organophosphate diazinon: data from a human volunteer study with oral and dermal doses. *Toxicol. Lett.*, 134, 105-113.
5. Gomes, J., Dawodu, A.H., Lloyd, O., Revitt, D.M., Anilal, S.V. (1999). Hepatic injury and disturbed amino acid metabolism in mice following prolonged exposure to organophosphorus pesticides. *Hum. Exp. Toxicol.*, 18, 33-37.
6. Morowati, M. (1997). Inhalation toxicity studies of thimet (phorate) in male swiss albino mouse, *Mus musculus*. I. *Hepatotoxicity. Environ. Pollut.*, 96, 283-288.
7. Yano, B.L., Young, J.T., Mattsson, J.L. (2000). Lack of carcinogenicity of chlorpyrifos insecticide in a high-dose, 2-year dietary toxicity study in Fischer. 344 rats. *Toxicol. Sci.*, 53, 135-144.
8. Solati, A., Tavasoli, A., Koohi, M. K., Marjanmehr, S. H., Nekouie Jahromi, O.A. (2011). The toxicopathologic effects of diazinon on histopathological, biochemical and hematological parameters in rabbits by dermal exposure of toxin. Tehran-Iran. *J. Vet. Res.* 66, 103-112.
9. Adedeji, O.B., Adedeji, A.O., Adeyemo, O.K., Agbede, S.A. (2008). Diazinon treated African catfish (*Clarias gariepinus*) showed unsettledness, increased exogenous stimulus sensitivity and postural disorientation. (Acute toxicity of diazinon to the African catfish (*Clarias gariepinus*)) *Afr. J. Biotechnol.*, 7, 651-654.
10. Armestrange, G., Bowen, D., Walker, C. (2008). Chronic hepatitis c in harrisons, principles of internal medicine. 17ed. Grown Hill, Brown Wold. chapter 298, 1808-1818.
11. Kanat Gulle, H., Demirin, D., Bayram, A. (2007). Effects of at different doses on rat liver and pancreas tissues, *Pest. Biochem. Physiol.*, (87):103-108.
12. Kalender, Y., Uzunhisarcikli, M., Ogutcu, A., Acikgoz, F., Kalender, S. (2005). Diazinon on pseudocholinesterase activity and haematological indices in rats: The protective role of vitamin E. *Environ. Toxicol. Pharmacol.*, 22:46-51.
13. Enan, E., Berberian, I. G., El-fiky, S., El-Masry, M., Enan, O.H. (1987). Effects of two organophosphorous insecticides on some biochemical constituent in the nervous system and liver of rabbits. *J. Environ. Sci., Health.* 22:149-170.
14. Zaahkouk, S.A.M., Helal, E.G.E., Abd-Rabo, T.E.I., Rashed, S.Z.A. (2000). Carbamate toxicity and protective effect of Vit. A and Vit. E on some biochemical aspects of male albino rats. *Egypt J. Hosp. Med.*, 1, 60-77.
15. Kappers, W.A., Edwards, R. J., Murray, S., Boobis, A. R. (2001). Diazinon is activated by CYP2C19 in human liver. *Toxicol. Appl. Pharmacol.* (177): 68-76.

16. Sams, C., Cocker, J., Lennard, M.S. ( 2003). Metabolism of chlorpyrifos and diazinon by human liver microsomes. *Toxicol. Lett.*, 144: 146.
17. Nakagawa, Y., Moore, G. (1999). Role of mitochondrial membrane permeability transition in p-hydroxybenzoate ester-induced cytotoxicity in rat hepatocytes. *Biochem. Pharmacol.* 58, 811-816.
18. Ansari, BA., Kumar, K. (1988). Diazinon toxicity: effect on protein and nucleic acid metabolism in the liver of zebrafish, *Brachydanio rerio* (Cyprinidae). *Sci Total Environ.*, 86(1): 63-8.
19. Mojabi A. (2000). Veterinary clinical biochemistry. Nourbakhsh Publication. Tehran, Iran.
20. Luskova, V., Svoboda, M., Kolarova, J. (2002). The effect of diazinon on blood plasma biochemistry in carp. *Acta. Vet. Berol.*, 71:117-123.
21. Anthony, E., Banister and Oloffs, P.C. (1986). Effect of sublethal levels of diazinon: histopathology of liver, *Bull. Environ. Contam. Toxicol.*, 37:501-507.
22. Banerjee, B.D., Seth, V., Bhattacharya, A., Pasha, S.T., Chakraborty, A.K. (1999). Biochemical effects of some pesticides on lipid peroxidation and free radical scavengers. *Toxicol. Lett.*, (107): 33-47.
23. Ashgar, M., Sheikh, M.A., Hashmi, A. (1994). Effects of orally fed methyl parathion on some hematochemical parameters of rabbits. *Pakistan. Vet. J.*, 14, 34-36.
24. Loumbourdis, N.S., Vogiatzis, A.K. (2002). Impact of cadmium on liver pigmentary system of the frog *Rana ridibunda*. *Ecotoxicol. Environ. Saf.*, 53, 52-58.